



# Removal of unwanted hair: efficacy, tolerability, and safety of long-pulsed 755-nm alexandrite laser equipped with a sapphire handpiece

Steven Paul Nistico<sup>1</sup> · Ester Del Duca<sup>2</sup> · Francesca Farnetani<sup>3</sup> · Stefania Guida<sup>3</sup> · Giovanni Pellacani<sup>3</sup> · Ali Rajabi-Estarabadi<sup>4</sup> · Keyvan Nouri<sup>4</sup>

Received: 30 January 2018 / Accepted: 5 April 2018  
© Springer-Verlag London Ltd., part of Springer Nature 2018

## Abstract

Due to the difference in refraction coefficients between air and the corneal epithelium, irradiation of the skin with a light source can lead to reflection of the energy and its leakage to the skin causes epidermal injury. All of which decreases the efficacy of treatment. We evaluated cooling sapphire handpieces' efficacy in decreasing pain and epidermal injuries and enhancing the treatment outcome in laser hair removal. A total of 49 patients with Fitzpatrick skin types of II to IV were treated for laser hair removal on face, limbs, inguinal, and axillary areas with pulsed 755-nm alexandrite laser equipped with a sapphire handpiece and the cooling system. Hair counts were performed by two independent observers at the baseline and 3 months after the final treatment. A marked reduction in hair regrowth was noted 3 months after the final treatment in all body locations studied. Clinical hair reduction was observed and fully assessed. There were no serious side effects with an average pain score of 4.6 out of 40. The cooled sapphire cylinder tip has been shown to minimize epidermal injury and reduce the system energy leaks to the skin.

**Keywords** Laser · Hair removal · Alexandrite · 755 nm

## Introduction

Laser devices are considered the most efficient methods for the reduction of unwanted hair [1]. The goal of these devices is to damage the bulge stem cell and the dermal papilla of the hair follicle by targeting melanin which represents the specific chromophore.

Several laser and light devices are available on the market for hair removal such as ruby laser (694 nm), alexandrite laser (755 nm), diode laser (800 nm), intense pulsed light (IPL) (590–1200 nm), neodymium-doped yttrium

aluminum garnet (Nd:YAG) laser (1064 nm), and light-based devices for home use [2–5]. Since the American Food and Drug Administration (FDA) approved the first laser therapy for epilation in 1996, much progress has been made in light-based technology and lasers.

Photo-epilation by alexandrite laser systems overall has been efficient means for hair removal, reducing hair growth by 70–80% after few laser sessions [6–8].

Nevertheless, laser hair removal has still some issues that may be improved. Although effective, laser treatment is associated with pain and side effects including temporary erythema, perifollicular edema, hypo- and hyperpigmentation, vesicle, and crusting, especially when treating dark or tanned skin [9–12].

Also, high concentrations of sub-micron nanoparticles have been shown to be released during laser hair removal. The fundamental concept of laser hair removal is the photothermal destruction of hair follicles. Melanin, the chromophore contained inside the hair shaft, absorbs the light, converting it into the heat, which then spreads to the bulge and the surrounding nonpigmented areas, endothelial cells for instance, with the risk of damaging them. Also, laser hair

✉ Steven Paul Nistico  
steven.nistico@gmail.com

<sup>1</sup> Department of Health Sciences, University of Catanzaro “Magna Graecia”, Viale Europa, Germaneto, 88100 Catanzaro, Italy

<sup>2</sup> University of Tor Vergata, Rome, Italy

<sup>3</sup> Department of Dermatology, University of Modena, Modena, Italy

<sup>4</sup> Department of Dermatology and Cutaneous Surgery, University of Miami Miller School of Medicine, Miami, FL, USA

removal often produces combustion of hair with a malodorous and visible plume [13]. Recently, it was demonstrated by Chuang et al., by gas chromatography-mass spectrometry (GC-MS), that the hair plume contains 13 known or suspected carcinogens and at least 20 chemical irritants that are potentially hazardous for laser practitioners [13]. That is why the use of smoke evacuators, good ventilation, and respiratory protection are highly recommended. In the attempt to create a safe work environment and to eliminate the need for smoke evacuators, custom ventilation systems, and respirators during laser hair removal, cold sapphire contact skin cooling is the best type of surface cooling [14]. Contact cooling cools the skin with temperature-controlled sapphire glass and a topical gel, prior to the delivery of the laser. Due to its contact with skin and use of topical gel, this type of surface cooling may have an additional benefit of plume suppression during laser hair removal.

This study evaluates the safety, tolerability, and efficacy of the long-pulsed 755-nm alexandrite laser (Motus AX, DEKA, Calenzano, Italy), equipped with a special handpiece with a cooled sapphire cylinder tip (Moveo technology, DEKA, Calenzano, Italy) that conveys the laser beam onto the patient's skin.

## Methods

A prospective review of the 49 patients treated for unwanted hair was made. Fitzpatrick skin types of patients ranged from II to IV. First, a screening of secondary causes of excessive hair growth was performed. Exclusion criteria included any previous laser treatments in the study area, hormonal dysfunction, isotretinoin use within the past year, history of photosensitivity, pregnancy, extreme tan, or a history of hypertrophic scars and keloids. All patients were asked to avoid any epilation techniques 4 weeks prior to laser hair removal. Shaving was carried out immediately before the procedure, as this allowed us to evaluate the characteristics of the follicles (follicle diameter and degree of pigmentation) and to adjust the treatment parameters accordingly. The participants' eyes were protected by suitable goggles.

All 49 patients completed four treatments at 4- to 6-week intervals and were available for final evaluation 3 months after their last treatment. All laser procedures were performed during the periods when patients' skin had little sun exposure. Subjects were also given questionnaires assessing laser tolerability and satisfaction. All patients signed informed consent forms.

During every session, the amount of pain evoked by the laser treatment was expressed by the participant and recorded on the numeric pain rating scale with a range from 0 (no pain) to 10 (unbearable pain). The pain scores for each treatment group were cumulative for all four therapeutic sessions (range

of 0–40 point. (At the final visit, subjects were asked to rank improvement for each area on a scale from 0 (not satisfied) to 5 (completely satisfied).

The treated area included face, limbs, inguinal, and axillary areas. Eight  $3 \times 2$ -cm areas were mapped and photographed. Sequential digital photographs using identical light, patient positioning, and camera equipment were obtained at baseline and at three-month follow-ups. Hair counts were performed manually counting and marking terminal hairs by two independent observers using digital photographs before treatment and during the final evaluation 3 months after the last treatment.

## Laser technique

The alexandrite laser (Motus AX, DEKA, Calenzano, Italy) system used in this study achieves a wavelength of 755 nm with a range of fluence between 6 and 8 J/cm<sup>2</sup>, with a spot size of 20 mm in diameter and frequency up to 10 Hz. The clinical characteristics of the patient (skin type and hair type) were used to select the ideal fluence for the procedure. No anesthetic cream was used before the treatment. The alexandrite laser was equipped with a special handpiece (Moveo, TM) with the cooling system integrated. After applying a transparent gel or oil, the Moveo handpiece was slid across the skin in a series of continuous circular or linear movements, aiming to pass several times over the same area. The repeated passes over small areas caused gradual heating of the vital parts of the hair leading to its destruction in a way that is painless for the patient. The achievement of adequate therapeutic dose in the area of  $10 \times 10$  cm was indicated by a special alarm from the device. After every treatment, a moisturizer for skin recovery was applied. Avoiding sun exposure was highly recommended, and patients were invited to apply sunscreen during the days following the session if the area was exposed.

## Results

Participants had a mean age of 32.6 years (21–44 years), and 40 patients were female (82%). Twenty-one volunteers (43%) had skin type II, 24 (49%) had skin type III, and 4 (8%) skin type IV. In total, 82 body areas were treated, 12 (15%) of which were on the groins, 10 (12%) on the face, 42 (51%) on the axillary region, and 18 (22%) on the limbs. The hair reduction was calculated by hair counting using digital photographs by the assessors at baseline and 3 months after the last treatment. Hair loss was defined as the percentage of terminal hairs absent after treatment compared with the number before treatment. We used the following hair reduction grading system: Zero indicated less than 25%; one, 25 to 50%; two, 51 to 75%; three, 76 to 90%; and four, greater than 90%.

A marked reduction in hair regrowth was noted 3 months after the final treatment in all body locations studied (Figs. 1 and 2). Clinical hair reduction scores on the face and inguinal area averaged 3.9 (Fig. 3). Hair on the legs was slightly more responsive with clinical hair reduction scores of 4.1. Axillary hair demonstrated the most impressive hair reduction scores, averaging 4.3.

### Side effects

The only side effect recorded during the treatment was light discomfort in some patients. This discomfort was managed by parameters adjustment, decreasing the fluence and/or increasing the pulse duration. Immediate side effects of the laser treatments included only perifollicular erythema. This side effect was transient and resolved within 2 days of onset in all patients. There were no incidences of blistering, dyspigmentation, scarring, cutaneous infection, and paradoxical hypertrichosis.

### Subject tolerability and satisfaction

Based on subject questionnaires, the long-pulse alexandrite laser with special handpiece was rated as almost not painful with mean pain scores of 4.6 out of 40. The bikini line and the face were the more sensitive areas with pain scores slightly higher than limb and axilla regions. At the final visit, according to the five-point satisfaction scale, alexandrite laser was found to be comparable with mean scores of 4.0.

### Discussion

Since 1997, the long pulse 755 nm alexandrite laser has been utilized with efficacy in laser hair removal [15]. The physical parameters within the specific devices vary considerably in terms of wavelength, pulse duration, spot size, and fluence.

When choosing treatment parameters, several factors must be considered, individually selected, and adjusted to the clinical situation before starting treatment sessions. The spot size which we used in all patients was set at 20 mm. A large spot size provides great penetration capacity for the radiation and can also allow for the more rapid treatment of large areas. The fluence ( $J/cm^2$ ) determines the temperature achieved within the follicular stem cells in the bulge while the pulse duration corresponds to the time length of that reached temperature. Fitzpatrick skin type and hair type are the main clinical characteristics to consider when selecting the form of treatment. The larger the size of the follicle and the higher its degree of pigmentation, the lower the fluence required for photothermolysis. Meanwhile, finer or less pigmented hairs will require higher fluences. We reconsidered fluence parameters at each treatment session. The progressive reduction in size of the follicles over successive sessions means that the initial treatment parameters will not be applicable in subsequent treatment sessions [16–18].

The long pulse 755 nm Alexandrite laser allows for deep penetration into the dermis permitting it to act on fair and black hair, but because of the competition with melanin, it is particularly indicated in patients with low skin types (up to 3–4) due to the risk of burning which results in hyper- or hypopigmentations. In order to counteract this problem, we used a specific handpiece with a cooled sapphire cylinder tip that conveys the laser beam into the patient's skin. First, selective cooling of the epidermis has been shown to minimize epidermal injury [19]. Second, the use of this sapphire guide drastically reduces the system energy leaks to the skin. When we irradiate the skin with a light source, because of the difference in refraction coefficients between air and the corneal epithelium, some of the radiation is reflected. This is a significant portion of energy lost during the treatment, which cannot be used for therapeutic purposes. Using the special handpiece, the laser-skin coupling is optimized by doubling the transmission of energy. The sapphire tip that comes in contact with the skin decreases the variation in the reflection index by reducing

**Fig. 1** The results of hair reduction in all studied body locations 3 months after the final treatment with 755-nm alexandrite laser Motus AX, D.E.K.A., Calenzano, Italy

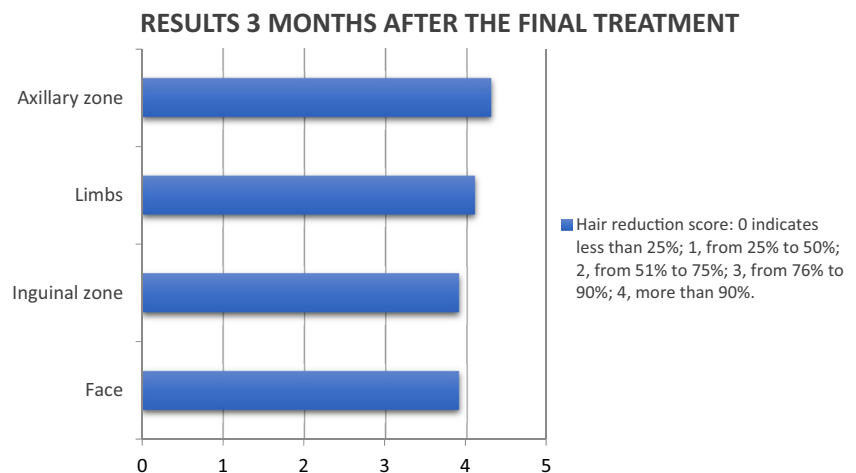
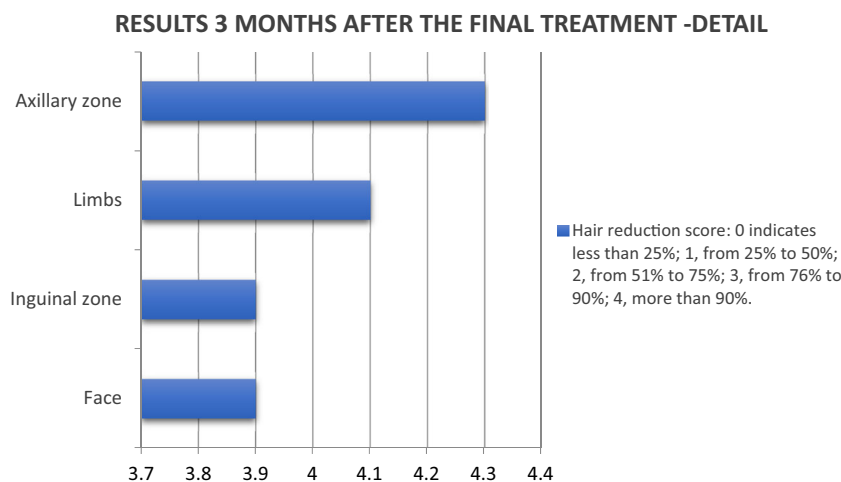


Fig. 2 Fig. 1 in detail



the reflected energy loss. Working at low fluences ( $6\text{--}8\text{ J/cm}^2$ ) makes the treatment painless. Some discomfort during treatment was the only side effect to be reported in patients receiving treatments to reasonably large areas on the limbs. The repeated passages over the same area make the treatment itself uniform without leaving untreated areas. If well performed, the repeat-pass technique with the Moveo handpiece reduces application times and makes it possible to treat particularly demanding skin areas quickly. Lowering the energy level not only results in less painful treatment but also reduces potential side effects. As we observed in our study, no serious side effects occurred during the treatment period.

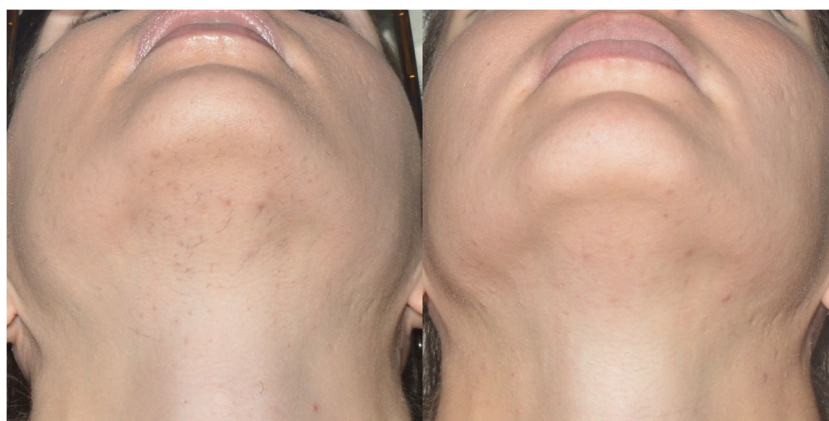Taking into consideration the outcomes of other papers where similar laser settings for hair removal were used with and without application of the cooled sapphire handpiece, we can confirm that laser hair removal with contact cooling produces significantly less nanoparticle plume when compared to treatments performed with cryogen-spray cooling and refrigerated air [14]. The use of gel, absence of dynamic air movement, and the close contact of the laser handpiece to skin all contribute to trapping and reducing free-floating nanoparticles.

Light absorption by melanin causes epidermal damage, which limits the maximum fluence that can be used in epilation procedures. Skin cooling is used to protect the epidermis during the laser treatment and to avoid the postinflammation hyperpigmentation. Air and contact cooling are the most popular methods. Contact cooling produces more effective and precise cooling of the skin thanks to an optimal sapphire-skin contact that is achieved by pressing the device firmly against the skin and by using a thin layer of high-thermal-conductivity liquid to fill in the skin microroughness.

Also, with this handpiece, a stable cooling during all the treatment is achieved. The epidermal temperature is significantly but harmlessly decreased by this method, while the matrix cells of the hair follicle temperature remain unchanged.

There are several limitations of this study: absence of control group, evaluation only the short term results of the hair removal treatment, and the method of assessment of hair counts. Hair counting by means of digital photographs could make possible that thin hairs after laser treatment were not noticed by assessors on the digital photographs, and thus, the percentage of hair reduction was higher.

**Fig. 3** A 29-year-old woman with Fitzpatrick skin type III who underwent treatment of unwanted hair in the face at **a** baseline and **b** 3-month follow-up after four treatments with 755-nm alexandrite laser Motus AX and Moveo technology, DEKA., Calenzano, Italy



## Conclusions

Few patients require the hair removal for a purely medical purpose such as those suffering from hirsutism, hypertrichosis, acne keloidalis nuchae, pseudofolliculitis barbae, or pilonidal disease [20, 21]. Most undergo these procedures for purely esthetic reasons like removing unwanted hair of the face, armpit, and genital area. When the approach is purely esthetic, the discomfort and the session duration is even more an important factor for the choice of the device and the progression of the treatments. In general, skin cooling is used to protect the epidermis during laser treatments in order to avoid the postinflammation hyperpigmentation.

In order to avoid this side effect, we used fairly low-energy levels. The sapphire handpiece gives the chance of administering a gradually increasing energy dose capable of damaging the hair bulb and achieving hair removal. Treatments are well tolerated by patients with only minimal discomfort.

On the other side, the use of sapphire contact cooling decreases significantly emission of plume that is an important issue in health care of laser practitioners.

In our experience, this new technique has proven to be effective, safe both for patients and laser operators, and fast as well. It has also proved to be popular among patients, especially as it causes no pain or irritation, a problem encountered with other hair removal systems.

## Compliance with ethical standards

**Conflict of interest** The authors declare that they have no conflict of interest.

**Ethical approval** All procedures were in accordance with the ethical standards of the institutional research committee and with the 1964 Helsinki declaration and its later amendments or comparable ethical standards.

## References

- Goldberg DJ (2007) Laser and light-based hair removal: an update. *Expert Rev Med Devices* 4(2):253–260
- Lorenz S, Brunnberg S, Landthaler M et al (2002) Hair removal with the long pulsed Nd:YAG laser: a prospective study with one year follow-up. *Lasers Surg Med* 30:127–134
- Gan SD, Graber EM (2013) Laser hair removal: a review. *Dermatol Surg* 39(6):823–838
- Grunewald S, Bodendorf MO, Zygouris A et al (2014) Long-term efficacy of linear-scanning 808 nm diode laser for hair removal compared to a scanned alexandrite laser. *Lasers Surg Med* 46(1):13–19
- Drosner M, Photoepilation AM (2005) Guidelines for care from the European Society for Laser Dermatology (ESLD). *J Cosmet Laser Ther* 7:33–38
- Davoudi SM, Behnia F, Gorouhi F et al (2008) Comparison of long-pulsed alexandrite and Nd:YAG lasers, individually and in combination, for leg hair reduction: an assessor blinded, randomized trial with 18 months follow-up. *Arch Dermatol* 144(10):1323–1327
- Toosi P, Sadighha A, Sharifian A et al (2006) A comparison study of the efficacy and side effects of different light sources in hair removal. *Lasers Med Sci* 21(1):1–4
- Freedman BM, Earley RV (2000) A structured treatment protocol improves results with laser hair removal. *J Cutan Laser Ther* 2:131–135
- Tierney EP, Goldberg DJ (2009) Laser hair removal pearls. *J Cosmet Laser Ther* 10(1):17–23
- Goldberg DJ (2006) Laser complications: hair removal. *J Cosmet Laser Ther* 8:197–202
- Kutlubay Z (2009) Alexandrite laser hair removal results in 2359 patients: a Turkish experience. *J Cosmet Laser Ther* 11:85–93
- Rasheed AI (2009) Uncommonly reported side effects of hair removal by long pulsed alexandrite laser. *J Cosmet Dermatol* 8:267–274
- Chuang GS et al (2016) Gaseous and particulate content of laser hair removal plume. *JAMA Dermatol* 152(12):1320–1326
- Ross EV, Chuang GS, Ortiz AE (2017) Airborne particulate concentration during laser hair removal: a comparison between cold sapphire with aqueous gel and cryogen skin cooling. *Lasers Surg Med*. <https://doi.org/10.1002/lsm.22772>
- Finkel B, Eliezri YD, Waldman A, Slatkine M (1997) Pulsed alexandrite laser technology for noninvasive hair removal. *J Clin Laser Med Surg* 15:225–229
- Ibrahimi OA, Avram MM, Hanke CW, Kilmer SL, Anderson RR (2011) Laser hair removal. *Dermatol Ther* 24:94–107
- Serrano-Grau P, Campo-Voegeli A, Fotoepilacion RD (2009) *Actas Dermosifiliogr* 100:351–361
- Haedersdal M, Beerwerth F, Nash JF (2011) Laser and intense pulsed light hair removal technologies: from professional to home use. *Br J Dermatol* 165:31–36
- Nelson JS, Majaron B, Kelly KM (2000) Active skin cooling in conjunction with laser dermatologic surgery. *Semin Cutan Med Surg* 19(4):253–266
- Khan MA, Javed AA, Govindan et al (2016) Control of hair growth using long-pulsed alexandrite laser is an efficient and cost-effective therapy for patients suffering from recurrent pilonidal disease. *Lasers Med Sci* 31(5):857–862
- Jasterzbski TJ, Schwartz RA (2015) Pseudofolliculitis cutis: a vexing disorder of hair growth. *Br J Dermatol* 172(4):878–884